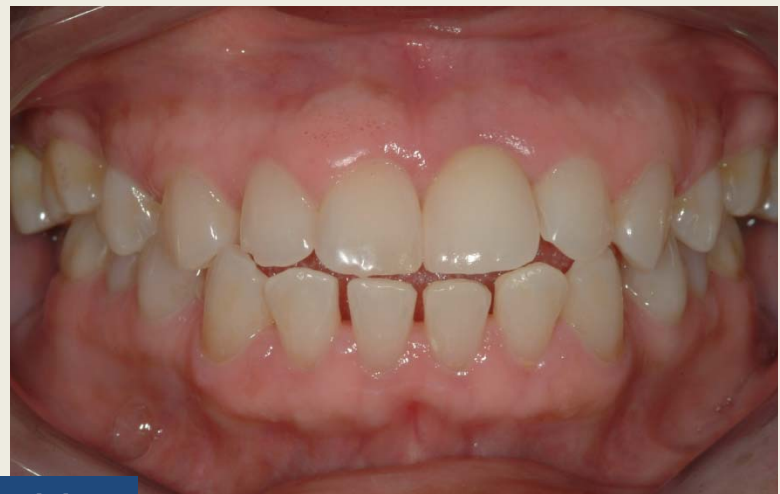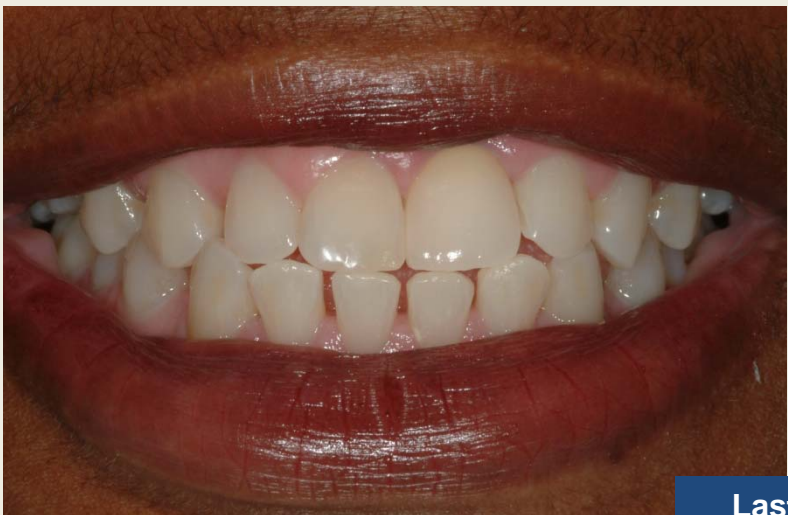
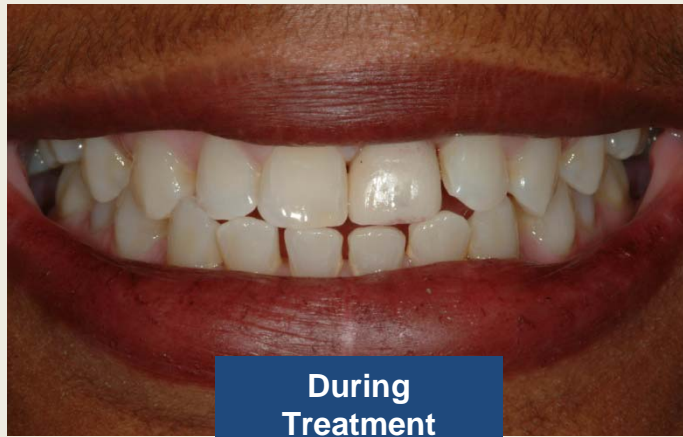

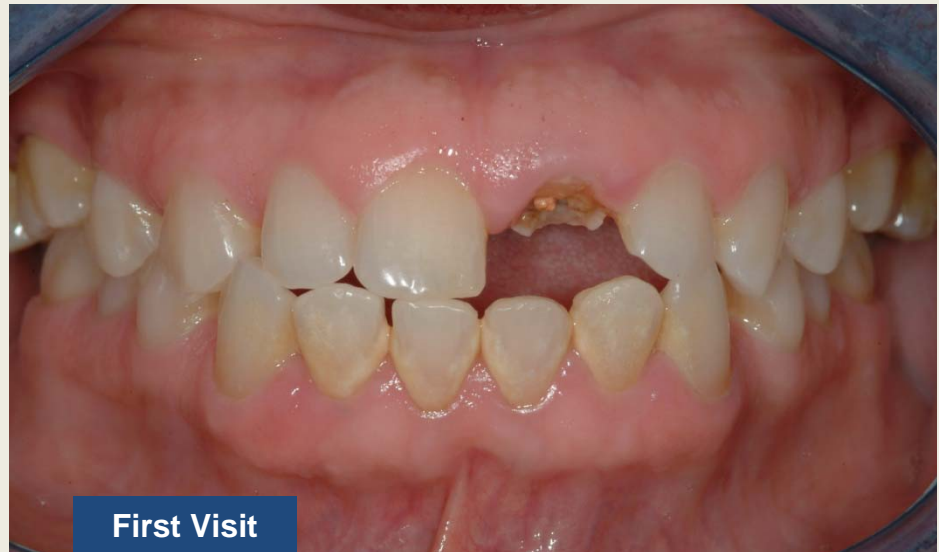
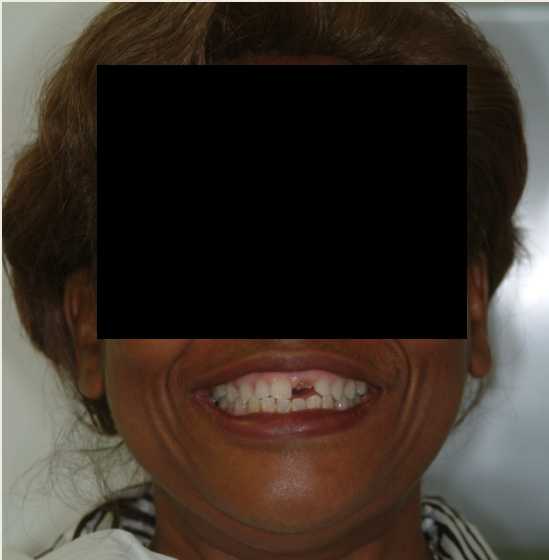Implant #9 with Crown

Background: V.R. had several crowns over many years on tooth #9. The tooth fractured again and she no longer wanted to have to worry about her front tooth. She chose to have an implant and a crown for #9. She wore a flipper during treatment. During treatment, V.R. required different procedures, ask Dr. Kubikian about more in-depth information.



Testimonial: "I had a fantastic experience. It was wonderful." V.R. - Pennsauken, NJ