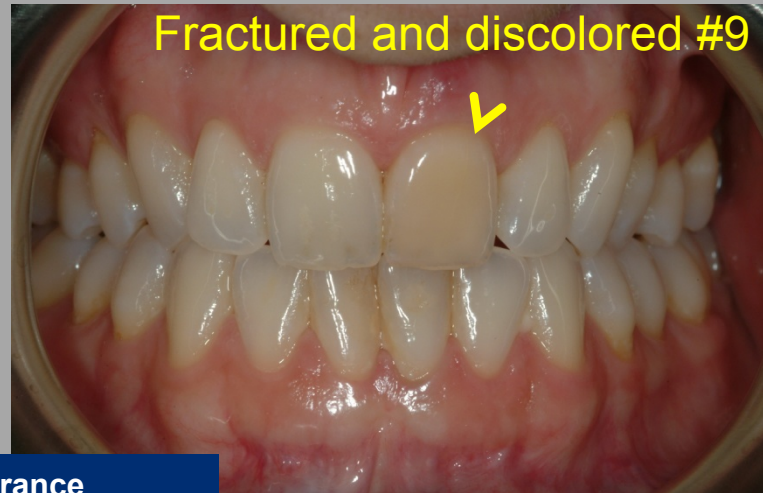
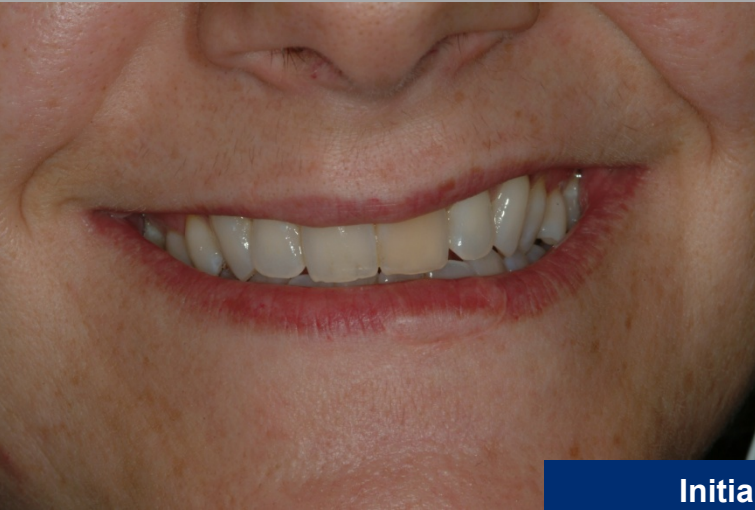
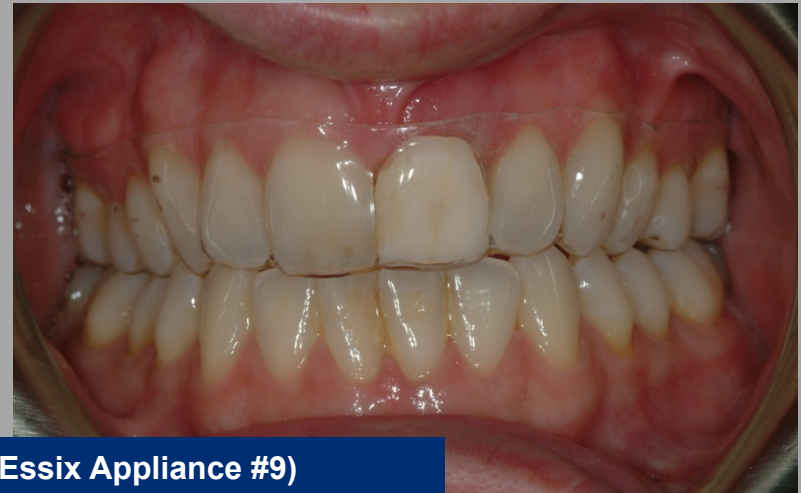
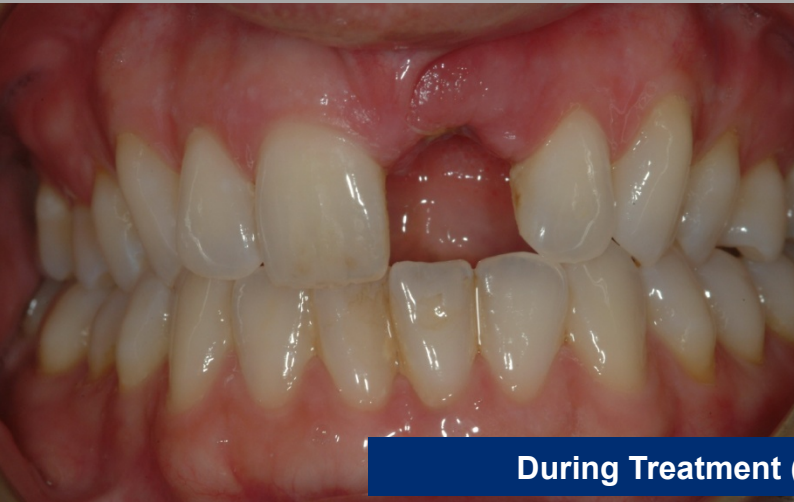# Implant #9 with Crown

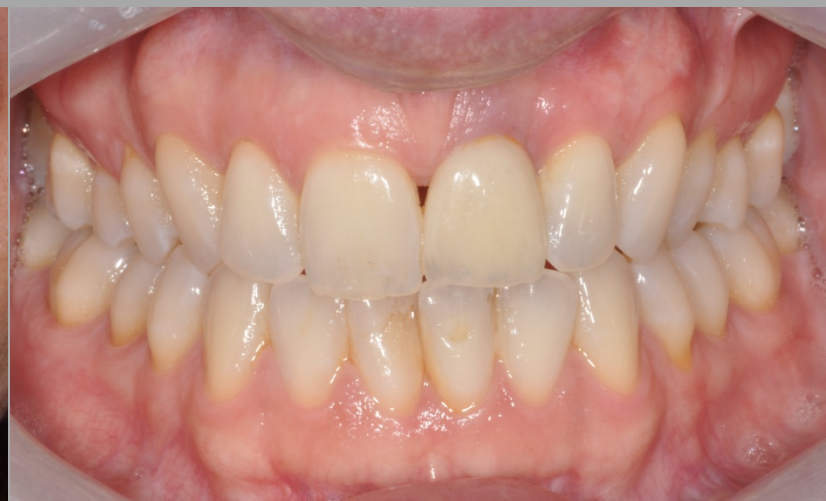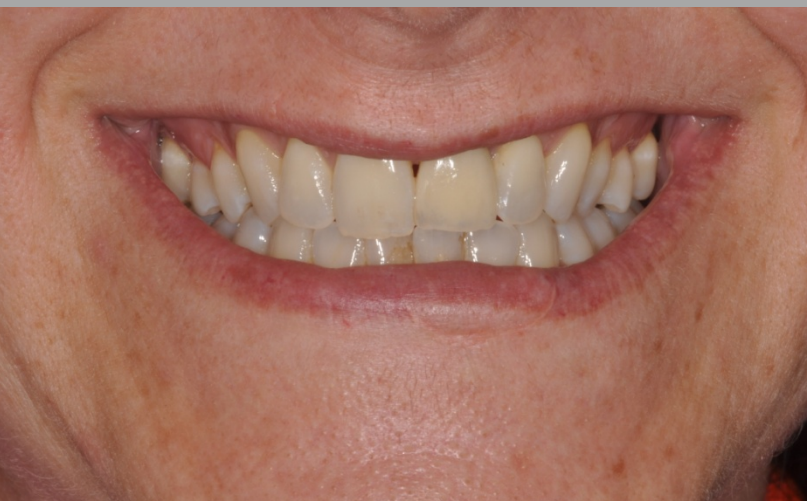**Background:** BB suffered a horizontal fracture on tooth #9 at a young age and now, 35 years later, must replace this tooth. Note the discoloration of the tooth as well.



Initial Appearance



During Treatment (Essix Appliance #9)



Final Tooth Implant Crown #9

**Testimonial:** "I wish I had gotten my wedding pictures taken after Dr. Kubikian did my front tooth implants..... You cannot even tell which tooth is fake! – BB, Deptford, NJ"